

(Fig. 3). The incisor relationship was corrected to normal and has been maintained for 18 months after the operation.

The subsequent tip rhinoplasty and shortening of the nose resulted in an improvement of the facial features. The psychological effect of this operation on the patient has been dramatic. His appearance is now relatively normal and this has made it easier for him to mix socially.

A Le Fort III osteotomy is a highly radical procedure and the duration of the operation described was 13 hours. Mid-face advancement may have to be performed at a young age to save the vision of the child, but this interferes with the growth of the bones. If there are no urgent

ocular indications for surgery, the operation should be delayed until growth has ceased. The most suitable age for operative correction of the mid-face is 16 years.

REFERENCES

1. Tessier, P. (1971): *Plast. reconstr. Surg.*, **48**, 224.
2. *Idem* (1971): *Ibid.*, **48**, 419.
3. *Idem* (1971): *Ibid.*, **48**, 533.
4. Converse, J. M., Wood-Smith, D. and McCarthy, J. G. (1975): *Ibid.*, **55**, 283.
5. Davies, D. W. and Munro, I. R. (1975): *Ibid.*, **55**, 55.
6. Dufourmentel, C. and Marchac, D. (1973): *Chirurgie*, **99**, 755.
7. Fleming, J. P. (1971): *Plast. reconstr. Surg.*, **47**, 560.
8. Murray, J. E. and Swanson, L. T. (1968): *Ibid.*, **41**, 299.
9. Obwegesser, H. L. (1969): *Ibid.*, **43**, 351.
10. Lewis, J. E. S. and Losken, H. W. (1975): *S. Afr. med. J.*, **49**, 1915.

The Diagnosis of Bilharziasis

J. SCHNEIDER, P. J. FRIPP

SUMMARY

In addition to the classical manifestations, bilharziasis may present with features which are atypical and which may simulate other conditions. In such cases the value of the previous history cannot be overemphasized. Immunodiagnostic procedures are useful pointers in diagnosis but in general treatment should be undertaken only after ova of the parasites have been found.

S. Afr. med. J., **51**, 536 (1977).

The features of bilharziasis range from an asymptomatic state to conditions in which, for example, lung or skin lesions dominate the clinical picture. Questions about exposure to bilharzia-infected waters should never be omitted in taking a history. Difficulty arises when sporadic

cases are encountered in areas where bilharziasis is not endemic, but a simple question with regard to bathing, paddling or boating would help to clarify the issue. The asymptomatic nature of the infection in many patients should be emphasized. One should consider the possibility of bilharzia even in the absence of the classic symptom of *Schistosoma haematobium* infection (terminal haematuria) or that of *S. mansoni* infection (diarrhoea). On the other hand the disease may have diverse manifestations and the clinical pictures often do not appear to have the slightest relation to bilharziasis. The diverse complications and clinical features of bilharzial infection can be illustrated by an analysis of a series of 50 patients, in the majority of whom bilharzia was diagnosed definitely by means of rectal biopsy examination, but in whom 'typical symptoms' appeared in a minority of cases. In this series,¹ rectal biopsy provided the initial definitive diagnosis in 34 of the 50 cases and it would seem an essential procedure regardless of symptoms. *S. mansoni* infections were symptomless in 13 out of 36 patients. Diarrhoea occurred in 11 out of 36 patients and was a presenting symptom of *S. haematobium* infection in 2 out of 14 patients.

Abdominal pain, a characteristic symptom of *S. mansoni* infection, was present in only 2 of the 36 patients with this infection. It may also be due to *S. haematobium*, and 5 out of the 14 patients with *S. haematobium* bilharziasis had abdominal pain as their initial symptom. In women the possibility of tubal bilharziasis merits consideration as a

Department of Medicine, University of the Witwatersrand and Johannesburg Fever Hospital (City Health Department)

J. SCHNEIDER, M.D., F.R.C.P., D.T.M. & H.

Bilharzia Research Unit, South African Institute for Medical Research, and Division of Parasitology, Department of Microbiology, School of Pathology, South African Institute for Medical Research and University of the Witwatersrand, Johannesburg

P. J. FRIPP, PH.D., F.I.BIOL., F.Z.S.

Paper presented at the Symposium on Bilharziasis, Nelspruit, Tvl, 30 August 1975.

cause of abdominal pain. Abdominal pain may also be due to appendiceal or peritoneal bilharziasis; the diverse clinical pictures produced by bilharzia were reflected in patients with central nervous system involvement, gynaecological involvement, and simulated, relapsing or manifest hepatitis. Constitutional symptoms — for example undue tiredness, feeling 'off colour', or inability to concentrate — may be features of either *S. mansoni* or *S. haematobium* infection. Almost a quarter of the patients had these nonspecific symptoms when they were first seen.

DEMONSTRATION OF PARASITES

Positive diagnosis of bilharzial infection is dependent on the demonstration of ova in rectal or other biopsy specimens, or in urine or stool.

Rectal Biopsy

Three or four rectal biopsy specimens should be taken from the region of the first rectal valve. They are pressed between two slides which are then held together by means of transparent adhesive tape applied to either end. This squash preparation should be immediately examined under a low-power microscope and not sent for section.

Biopsy of rectal mucosae is ideal for the diagnosis of bilharzial infection, because (a) a definite diagnosis can be made within a few minutes; (b) fresh rectal biopsy specimens make possible the diagnosis of *S. mansoni* and of *S. haematobium* infection (in addition, animal schistosome ova (*S. matheei*) may be observed); (c) it makes stool examination unnecessary and, in the case of *S. haematobium* infection, may prevent waste of time on urine examination.

S. haematobium ova in rectal biopsy material are usually non-viable. This does not mean that the patient has an inactive infection, since he may be passing viable ova in the urine at the same time.

Contraindications to rectal biopsy. Biopsies should be avoided in the very young and the old. Biopsies should not be done in patients with severe anaemia, in those taking anticoagulants or in those with a known bleeding tendency. Friedheim² also recommends that rectal biopsy should not be done in acutely febrile patients except when the possibility of acute bilharziasis exists. The only complication likely to follow rectal biopsy is bleeding which can usually be controlled by direct pressure to the bleeding areas with a pledget of cottonwool held in an artery forceps. If this is not helpful, 10% silver nitrate applied to the bleeding areas will usually stop the haemorrhage. We have done innumerable rectal biopsies, and had to use electrocauterization only once.

Urine Examination

Urinary bilharziasis cannot be excluded with certainty merely by examining several single specimens of urine, or by examining a sample of urine taken after exercise, or even by examining a 24-hour specimen of urine.

The following points indicate why urine examinations may have limited value: (a) egg output shows a diurnal

pattern; if a single specimen of urine is to be examined, one taken in the early afternoon is most likely to reveal ova of *S. haematobium*^{3,4} (Fig. 1); (b) repeated examinations of urine may be necessary if the diagnostic yield of schistosome ova is to be raised above 20% in cases of bilharzial cystitis;⁵ (c) the corollary to this is that the number of eggs discharged in the urine may vary widely from day to day; this underlines the importance of not relying on the results of examinations of single specimens of urine;⁶ (d) the belief that examination of the last amount of the urine passed gives a greater chance of demonstrating eggs does not seem to be correct, as *S. haematobium* ova are found throughout the urinary stream regardless of whether the infection is heavy or light.⁷

'Pus cells' in the urine should not lead to a mistaken diagnosis of associated bacterial infection, since secondary bacterial infection of the bladder is uncommon. Such cells may in fact be eosinophils derived from peri-ovular inflammatory lesions in the bladder wall.⁸

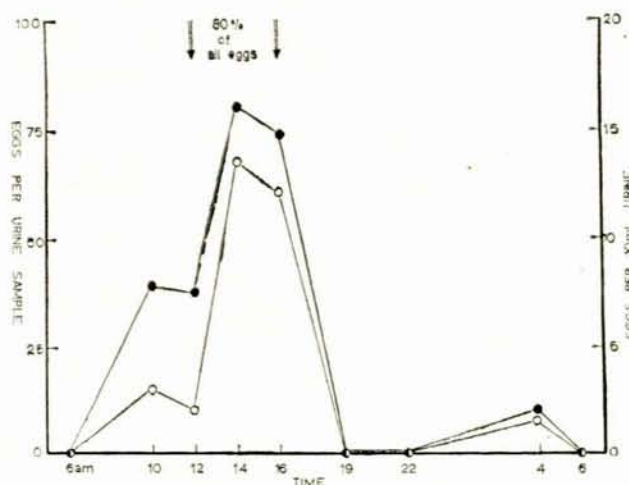


Fig. 1. Diurnal variation in output of *S. haematobium* eggs in the urine (●—● expressed as eggs per urine sample; ○—○ expressed as eggs per 10 ml urine). The total output over the 24-hour period was 253 eggs.

Stool Examination

One of the points given in favour of rectal biopsy is that it avoids protracted and messy stool concentration techniques. Visser and Pitchford,⁹ however, have developed a rapid, simple and quantitative method for the recovery of *S. mansoni* eggs from the excreta, by utilizing nylon gauze filters.

SEROLOGICAL DIAGNOSIS

A positive serological test for bilharziasis does not, as a general rule, give the green light for immediate treatment, since it provides only indirect evidence of a bilharzial infection. In 1972 Kagan¹⁰ observed: 'With the proper antigen the complement fixation test is probably the best serologic procedure for the diagnosis of schistosomiasis'. Kagan thought that the fluorescent antibody test was a 'useful diagnostic and epidemiologic tool'. However, he stressed

the fact that 'In Africa, the use of fluorescent antibody tests for diagnosis is creating a problem because a positive test is being used as a basis for treatment'. He made the point that exposure to avian schistosomes was also capable of inducing antibody formation.

Treatment on the basis of a positive serological test alone cannot be too strongly condemned. A positive serological test should stimulate attempts to make a definitive diagnosis. If schistosome eggs are not seen after an intensive search and if the clinical picture is highly suggestive of bilharziasis, the degree of positivity of the serological test should be taken into account. Thus a bilharzial complement fixation test of 3+ or 4+ may suggest the possibility of active disease, as would an increasing titre. This is by no means an academic view, since there are cases on record of bilharziasis of the central nervous system where ova were absent from the bladder and/or bowel and yet the bilharzial complement fixation test was strongly positive. This apparently anomalous situation of a positive serological test without demonstrable parasites may arise in a number of circumstances: (a) in the acute invasive stage of the disease (Katayama disease) when the larval schistosome is migrating from the skin to the liver and oviposition has not yet started; (b) in a very light (subclinical) infection; (c) in a predominantly unisexual infection; (d) when the infection is in an ectopic site.

If a serological test is positive and one cannot demonstrate schistosome ova, this finding must be considered in relationship to possible exposure to infection and other facets of the history and to the results of other investigations. Perhaps the best approach is that suggested by Gelfand:¹¹ 'Providing the patient gives a history of proper exposure to the infection and provided two of the following criteria are positive, a course of treatment may be considered: (i) blood eosinophilia; (ii) a positive allergic reaction to any of the following: (a) fluorescent antibody test; (b) intradermal or complement fixation test; (iii) a previous history of terminal haematuria; (iv) a previous history suggestive of kabure itch or Katayama syndrome; (v) a history of exposure to the infection together with others (if one of the group is known to be passing ova in the urine or stool, it is probable that the patient with whom we are concerned has also acquired the disease); (vi) a dilated ureter on intravenous pyelography.'

Attention should be drawn to the fact that a negative serum test does not necessarily exclude the possibility of bilharzial infection. In long-standing infections positivity tends to wane.

PHYSICAL EXAMINATION AND SPECIAL INVESTIGATIONS

Physical Examination

Physical examination is often of no assistance, but it should never be omitted. Thus one may discover kidney swellings due to hydronephrosis or palpate a 'tubo-ovarian mass' which turns out to be due to fallopian tube bilharziasis, or pulmonary hypertension may be discovered which could be due to an obliterative arteriolitis initiated by ova, or a palpable bladder mass which points to the likelihood of a complicating carcinoma.

Intravenous Pyelography

In any patient with bilharzial infection structural disease of ureters and bladder must be ruled out. Although urinary tract involvement is uncommon with *S. mansoni*, infections with both parasites are not at all uncommon. Ideally intravenous pyelography should be carried out in all patients with bilharzial infection when the earliest sign of ureteric disease is a persistent filling of the lower segment of the ureter. Cystoscopy and retrograde pyelography could also be used to assess the effects of treatment.

Radiological evidence of bilharzial lesions of the urinary tract does not necessarily imply irreversibility. Farid *et al.*¹² found radiological and functional improvement in 7 out of 10 patients, 2-3 months after antibilharzial treatment. Nodular filling defects in the bladder and hydronephrosis disappeared, although treatment was less successful in older patients.

Radiography of the Pelvis

This investigation is used to detect calcification of the bladder which is a feature of advanced chronic bilharziasis. This is a rare finding in Whites. In endemic areas it will bring to light cases of advanced bilharziasis in Blacks.

Other Investigations

Blood counts and blood urea estimations should be done. Eosinophilia is not an invariable finding and is encountered less frequently in chronic cases. Blood urea estimation is necessary because renal function may be impaired.

Sigmoidoscopy and proctoscopy for the investigation of intestinal bilharziasis have been used in various parts of the world. In South Africa it is very uncommon to find specific mucosal changes in colorectal bilharziasis. In fact, a normal-looking bowel mucosa may harbour a bilharzial infection.

Gynaecological investigations. Gynaecological bilharziasis is a common manifestation of the disease, and two diagnostic methods are important. Cervical smears¹³ may reveal ova of *S. haematobium*, *S. mansoni* and the cattle schistosome, *S. matthei*. Laparoscopy could help in the diagnosis of fallopian tube infection.

Central nervous system investigations. Bilharziasis has a propensity to involve the central nervous system and particularly the spinal cord. Intracranial bilharziasis may also occur and 9 such patients, most of whom presented with seizures, were described by Levy *et al.*¹⁴ In spinal bilharziasis the initial diagnosis is often 'paraplegia of unknown cause' or 'transverse myelitis'.

The following findings may point to spinal bilharziasis: (a) blood eosinophilia with leucocytosis; (b) spinal fluid pleocytosis with elevation of spinal fluid protein and normal spinal fluid glucose; (c) spinal fluid eosinophilia;¹⁵ (d) positive bilharzial immunoserology; (e) a positive circumoval precipitin test in the cerebrospinal fluid has been used in the Philippines for the diagnosis of cerebral bilharziasis due to *S. japonicum* and it is therefore suggested that immunodiagnostic tests be carried out on the cerebrospinal fluid of patients suspected of having spinal (or cerebral) bilharziasis.

Investigation of kidney lesions. Silva *et al.*¹⁶ found electron-dense deposits in the basement membranes of glomeruli as well as laminated bodies near the mesangial cells in patients with *S. mansoni* infection. The circulating soluble antigen and antibody level in human bilharziasis may have a bearing on schistosome-related immune complex disease, particularly the nephrotic syndrome.¹⁷ As yet, no such kidney complication of bilharziasis has been reported in South Africa.

CLINICAL SYMPTOMATOLOGY

Stages of Disease

A discussion of the stages of bilharzial infection helps in the understanding of its numerous facets and their genesis, as well as pinpointing such facets from the diagnostic aspect.

Stage I — invasive stage. A schistosome dermatitis may be seen after one or many exposures to cercariae and seems to be a sensitization phenomenon.

Stage II — Katayama disease. . . . a self-limited febrile illness . . . has been reported to occur largely on primary and massive exposure to infection, and has been postulated to represent a form of serum sickness.¹⁸

Stage III — localized disease or established infection. Edington and Gilles¹⁹ consider this to be an early chronic stage which manifests, for example, with haematuria or diarrhoea. Fibrosis is not marked and is a local inflammatory response to schistosome ova.

Stage IV — chronic stage. This stage is probably associated with delayed hypersensitivity-type granulomatous inflammation, in which inflammatory and fibrotic obstruction to the passage of blood and urine may be observed.¹⁹

Stage V — stage of late infection. This is a chronic disease state in which patients present with cor pulmonale, obstructive uropathy, renal failure and portal hypertension. The pathology is a 'progressive formation varying with intensity of infection and possibly other factors'.¹⁹

The Stage of Invasion and Migration

This is the stage before the worms have matured and before deposition of ova has started.

During this stage the diagnosis may be confirmed only on the basis of a positive bilharzial complement fixation (or other serological) test. The complement fixation test may become positive as early as 3 weeks after exposure to infection. However, there are other signs and symptoms which may assist in making a clinical diagnosis, and for this reason a detailed description of Katayama disease is given below. Another point worth bearing in mind is that this allergic or invasive phase of the disease may not be benign and may give rise to a severe and potentially life-threatening situation.

This stage encompasses both penetration of the skin by cercariae and the subsequent migration of the schistosomes through the system. The initial skin eruption associated with cercarial penetration has been referred to as 'bilharzial itch', as opposed to the 'swimmer's itch' which follows exposure to animal cercariae. Migration through the system produces characteristic signs and symptoms

referred to as Katayama syndrome or Katayama disease. This, of course, is merely the name for the allergic or invasive phase which occurs 4-10 weeks after exposure to cercariae. Kabure itch or Katayama disease is rarely encountered in Blacks from endemic areas and Gelfand asserts that they seem to occur only in non-immune populations, such as the Whites.

The classic manifestations of the Katayama syndrome or Katayama disease are fever, cough, tender enlargement of liver and spleen, urticaria and blood eosinophilia. In 1970, Clarke *et al.*²⁰ described the features of this condition in 22 White and 2 Black patients who had visited the Rhodesian lowveld. Urticaria was seldom seen but most patients had an itch, pyrexia, cough, weight loss and eosinophilia. Diarrhoea was reported in 10 patients and liver tenderness in a similar number. Only 2 had hepatomegaly. An interesting observation was that several patients had mental symptoms. In 1967, Zilberg *et al.*,²¹ also from Rhodesia, documented 3 cases of Katayama fever in children. One of these presented with acute encephalopathy with disturbances of consciousness and extensor plantar responses. The 2 other patients showed cardiac abnormalities and 1 of these had an abnormal EEG. On this basis Zilberg *et al.*²¹ were able to point to both cerebral and cardiac abnormalities in Katayama fever.

Hepatic Bilharziasis

In 1965 Bhagwandeem,²² in Durban, suggested that hepatic bilharziasis had not as yet received serious consideration in South Africa. He had shown that *S. mansoni* did produce lesions, the severest form being bilharzial hepatic fibrosis or 'pipe-stem cirrhosis'. The important question arising out of Bhagwandeem's observations was how frequently liver involvement produced clinical disease. The problem of portal hypertension due to bilharzial hepatic fibrosis has merited further work. Nel *et al.*²³ studied 51 patients with histological evidence of hepatic bilharziasis (*S. haematobium* 92.3%; *S. mansoni* 73%; both 65.4%). The clinical presentations were, as expected, hepatomegaly and splenomegaly in all and anaemia in about two-thirds of patients. Malnutrition and retardation of growth were observed in 58%, ascites in 36% and upper gastro-intestinal haemorrhage in 6%. Certain of the special investigations proved very interesting. Thus haematological studies disclosed hypersplenism in just over half. Decreased or normal serum albumin levels were detected but gamma-globulin levels were markedly increased. Transaminase activity was normal or slightly increased and alkaline phosphatase levels were increased. Six patients were found to have oesophageal varices on radiological study of the upper gastro-intestinal tract and they all had hypersplenism, of which Nel *et al.*²³ could distinguish two types: (i) reversible hypersplenism associated with acute portal hypertension and due to early liver involvement, which was observed in 7 patients and was reversed on medical treatment; (ii) irreversible hypersplenism in conjunction with severe hepatofibrosis. 'This was noted in all cases with varices and it can be concluded that the presence of varices denotes a chronic irreversible phase of the disease with severe presinusoidal hyperplasia'.²³ In 16 of their patients hypersplenism was a persistent

feature 6 weeks after medical treatment and they were referred for surgery.

Bilharzial Pulmonary Hypertension

Bilharzial pulmonary hypertension was first reported in South Africa in 1969 by Winship *et al.*²⁴ who described 5 cases in Black children in Durban, of whom 3 died. Postmortem examinations were carried out and histology disclosed the presence of vesical and colonic bilharziasis in all cases. Histology of the lungs revealed marked obliterative changes involving arterioles and also numerous angiomatoid lesions. The latter were thought to indicate chronic pulmonary hypertension, which exemplifies one of the manifestations of the stage of late infection.

Cutaneous Bilharziasis

This is due to the presence of adult worms and eggs in the skin. In 1973 Ramos,²⁵ from Mozambique, noted the high incidence of asymptomatic deposition of eggs in the skin, most commonly in the genital and perigenital areas. Previously, Findlay and Whiting²⁶ had reported on 5 patients with lesions on the trunk due to cutaneous bilharziasis. Four of these patients had *S. haematobium* infection and they presented with zosteriform lesions of the trunk on that side of the body lying uppermost during sleep.

Abdominal Pain and Bilharzial Infection

Seven of the 50 patients whom we saw personally had abdominal pain as their presenting symptom. This symptom was most common in the *S. haematobium* group (5 out of 14). Pain was found to be due to fallopian tube involvement, peritoneal bilharziasis, appendiceal infection, or the presence of granuloma at the lower end of one ureter. The fifth patient in the *S. haematobium* group experienced pain over the lower mid-abdomen. This was thought to be due to bladder involvement, since subsequent examination disclosed the presence of large numbers of viable *S. haematobium* ova in the urine.

There were only 2 patients (out of 36) in the *S. mansoni* group in whom abdominal pain was the initial symptom of the disease. It is, however, not uncommon for abdominal pain to be associated with diarrhoea in *S. mansoni* infection.

Bilharziasis and Abdominal Tumours

Bilharziasis as a cause of abdominal tumours must always be considered in the differential diagnosis. Stephens²⁷ cites the case of a Black woman with a mass in the left lower abdominal quadrant in whom the possibility of sigmoid

carcinoma was considered. At exploratory laparotomy the appearance was that of carcinoma involving the entire left colon with serosal implants. Histological examination revealed this to be a fibrosing granuloma, and ova of *S. mansoni* were found in a digest of a portion of the mass.

Bilharziasis and Scholastic Ability

One of our patients was a 13-year-old White boy with an *S. mansoni* infection who found difficulty in concentrating during school hours. Clarke and Blair²⁸ found a definite relationship between educational achievement and infection in a study of White schoolboys in Salisbury. This was substantiated in 1974 by Castle *et al.*²⁹ who thought that there was some evidence that active bilharziasis adversely affected spatial relationships and numerical abilities, functions which could be diminished by fatigue. In South Africa, Walker *et al.*³⁰ maintained that in Black children bilharziasis produced no detectable disability in terms of growth, physical activity and intelligence, a situation which Clarke and Blair²⁸ had also noted.

REFERENCES

- Schneider, J. (1970): Paper read at 4th World Congress of Gastroenterology, Copenhagen.
- Friedheim, E. A. H. in Hawking, F., ed. (1973): *Chemotherapy of Helminthiasis*, vol. 1, p. 57. Oxford: Pergamon Press.
- Stimmel, C. M. and Scott, J. A. (1956): *Tex. Rep. Biol. Med.*, **14**, 440.
- Onori, E. (1962): *Ann. trop. Med. Parasit.*, **56**, 292.
- Kark, A. E. (1961): *S. Afr. med. J.*, **35**, 215.
- Gerritsen, T., Walker, A. R. P., De Meillon, B. and Yeo, R. M. (1953): *Trans. roy. Soc. trop. Med. Hyg.*, **47**, 134.
- Gove, R. B. (1962): *Ibid.*, **56**, 74.
- Powell, S. J., Maddison, S. E. and Elsdon-Dew, R. (1965): *S. Afr. med. J.*, **39**, 166.
- Visser, P. S. and Pitchford, R. J. (1972): *Ibid.*, **46**, 1344.
- Kagan, I. G. in Cahill, K. M., ed. (1972): *Clinical Tropical Medicine*, vol. II. Baltimore: University Park Press.
- Gelfand, M. (1975): *Medicine SA*, **26**, 1426.
- Farid, Z., McConnell, E., Bassily, S., Schubert, A., Sabour, M. and Abdel Wahab, M. F. (1967): *Lancet*, **2**, 1110.
- Koller, A. B. (1975): *S. Afr. med. J.*, **49**, 1228.
- Levy, L. F., Baldachin, B. J. and Clain, D. (1975): *Cent. Afr. J. Med.*, **21**, 76.
- Zilberg, B. (1967): *S. Afr. med. J.*, **41**, 783.
- Silva, L. C., Brito, T., Camargo, M. E., De Boni, D. R., Lopes, J. D. and Gunji, J. (1970): *Bull. Wld Hlth Org.*, **42**, 907.
- Madwar, M. A. and Voller, A. (1975): *Brit. med. J.*, **1**, 435.
- Warren, K. S. (1973): *J. infect. Dis.*, **127**, 595.
- Edington, G. M. and Gilles, H. M. (1969): *Pathology in the Tropics*, p. 159. London: Edward Arnold.
- Clarke, V. de V., Warburton, B. and Blair, D. M. (1970): *Cent. Afr. J. Med.*, **16**, 123.
- Zilberg, B., Sanders, E. and Lewis, B. (1967): *S. Afr. med. J.*, **41**, 598.
- Bhagwande, S. B. (1965): 'The clinico-pathological manifestations of schistosomiasis in the African and Indian in Durban', M.D. thesis University of Natal, Pietermaritzburg.
- Nel, C. J. C., Honiball, P. J. and Van Wyk, F. A. K. (1974): *S. Afr. J. Surg.*, **12**, 233.
- Winship, W. S., Kallichurum, S. and Lapinsky, G. B. (1969): *S. Afr. med. J.*, **43**, 423.
- Ramos, S. F. (1973): *Ibid.*, **47**, 2003.
- Findlay, G. H. and Whiting, D. A. (1971): *Brit. J. Derm.*, **85**, suppl. 7, p. 98.
- Stephens, R. R. (1966): *Cent. Afr. J. Med.*, **12**, 28.
- Clarke, V. de V. and Blair, D. M. (1966): *Ibid.*, **12**, 25.
- Castle, W. M., Clarke, V. de V. and Hendrikz, E. (1974): *S. Afr. med. J.*, **48**, 2035.
- Walker, A. R. P., Walker, B. F. and Richardson, B. D. (1970): *Amer. J. trop. Med. Hyg.*, **19**, 792.