

Application in Europe of a urine-based rapid diagnostic test for confirmation of *Schistosoma mansoni* infection in migrants from endemic areas

S L Becker (soeren.becker@uks.eu)^{1,2,3}, H Marti^{3,4}, S Zimmermann⁵, D Vidacek⁵, M Herrmann¹, J Utzinger^{2,3}, P A Schnabel⁶, R M Bohle⁶

1. Institute of Medical Microbiology and Hygiene, Saarland University, Homburg/Saar, Germany
2. Department of Epidemiology and Public Health, Swiss Tropical and Public Health Institute, Basel, Switzerland
3. University of Basel, Basel, Switzerland
4. Department of Medical Services and Diagnostic, Swiss Tropical and Public Health Institute, Basel, Switzerland
5. Department of Medicine II, Saarland University, Homburg/Saar, Germany
6. Institute of Pathology, Saarland University, Homburg/Saar, Germany

Citation style for this article:

Becker SL, Marti H, Zimmermann S, Vidacek D, Herrmann M, Utzinger J, Schnabel PA, Bohle RM. Application in Europe of a urine-based rapid diagnostic test for confirmation of *Schistosoma mansoni* infection in migrants from endemic areas. *Euro Surveill.* 2015;20(23):pii=21151. Available online: <http://www.eurosurveillance.org/ViewArticle.aspx?ArticleId=21151>

Article submitted on 27 May 2015 / published on 11 June 2015

In February 2015, a male patient from Eritrea with persistent abdominal pain and rectal bleeding was diagnosed with *Schistosoma mansoni* infection upon examination of a rectal biopsy. In May 2015, repeated stool microscopy identified *S. mansoni* infection in another Eritrean patient with abdominal pain and considerable eosinophilia (34%). Use of point-of-care circulating cathodic antigen (POC-CCA) tests on urine confirmed *S. mansoni* infection in both patients. Wider application of non-invasive POC-CCA urine tests will improve schistosomiasis diagnosis and clinical management in migrants.

We report the application of a urine-based antigen detection test for rapid, non-invasive diagnosis of intestinal schistosomiasis in two migrants from Eritrea. The potential implications of this rapid and highly sensitive diagnostic test with a short turn-around time for improved migrant health in European hospital settings and travel clinics are discussed.

Descriptions

Patient 1

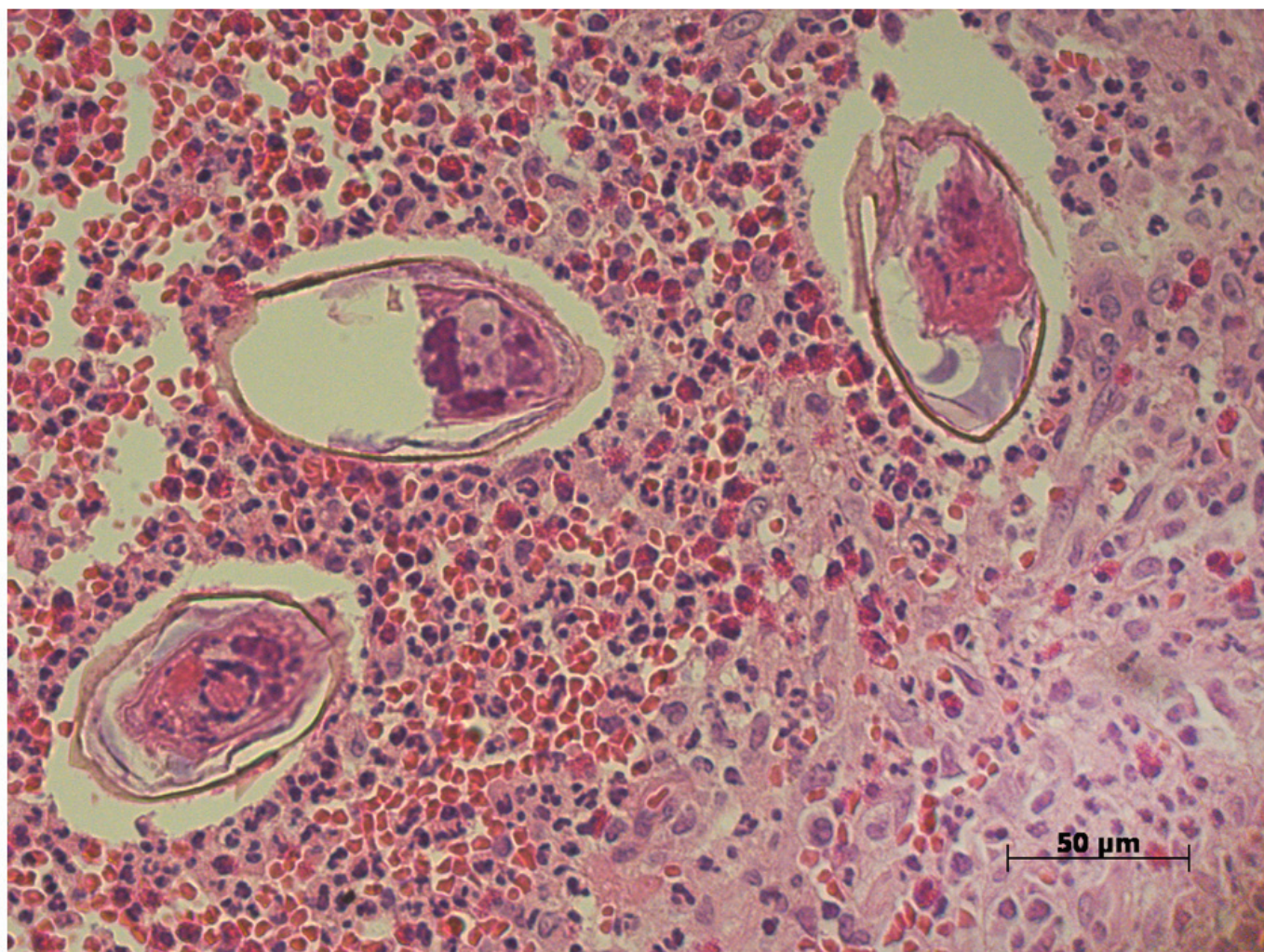
At the beginning of February 2015, a previously healthy male patient from Eritrea in his late teens presented to a German hospital with a history of rectal bleeding during the preceding days and persistent abdominal pain that had lasted for several weeks. No diarrhoea and no further digestive symptoms were reported at the time of presentation. The patient did not take any medication and past medical history was unremarkable. He was of Eritrean origin and had migrated to Germany approximately one year before presenting at the hospital. On physical examination, the patient was afebrile, vital signs were normal and no abdominal

abnormalities were noted. However, rectal examination revealed a small, palpable mass, located approximately 7 cm from the anal verge. Blood tests showed a normal white blood cell count (5,800 cells/mL) with 6% eosinophils. Liver function tests and C-reactive protein were normal. Flexible colonoscopy identified two polyp-like lesions in the rectum, measuring up to 20 mm and 3 mm, respectively, while the rectal mucosa appeared macroscopically normal. Polypectomy was performed and biopsies were taken for histological workup, which showed erosive lesions and chronic intestinal inflammation. Upon microscopic examination of both polyps, typical pathognomonic features of eggs of the blood fluke *Schistosoma mansoni* were observed (Figure 1). Distinct histopathological features were the unique shape and size of parasite eggs (measuring 130–140 × 50–60 µm and lateral spine) and the eosinophil infiltration around the granulomas.

A stool sample could not be obtained from the patient. However, a urine sample was subjected to a rapid point-of-care (POC) antigen test. This test detects a schistosome-excreted circulating cathodic antigen (CCA). This POC-CCA test is commercially available (Rapid Medical Diagnostics; Pretoria, South Africa) and has been validated in various schistosomiasis-endemic settings of sub-Saharan Africa, where it proved more sensitive for *S. mansoni* than stool microscopy using the Kato-Katz technique [1]. Indeed, the reported sensitivity and specificity of the POC-CCA urine test for *S. mansoni* diagnosis during a multi-centre evaluation in five African countries were in the range of 78–92% and 56–94%, respectively, whereas the estimated sensitivity of the Kato-Katz technique was 44–77%. The POC-CCA in our patient with histologically proven schistosomiasis gave a faintly positive test line (termed ‘trace’ and

FIGURE 1

Biopsy of a rectal polyp, with typical granulomatous lesions with eosinophil infiltration, in a patient with intestinal schistosomiasis, Germany, February 2015



Haematoxylin and eosin, original magnification x40.

considered to be positive by the manufacturer) (Figure 2), thereby confirming the suitability of this non-invasive test to be employed in the diagnostic workup of patients with suspected schistosomiasis.

Abdominal ultrasound examination was performed to exclude hepatic fibrosis and other indicators of *Schistosoma*-induced chronic morbidity. The patient was treated with praziquantel, 40 mg/kg for three consecutive days [2], which led to complete resolution of clinical symptoms.

Patient 2

While preparing this report, we observed in May 2015 another young male patient from Eritrea with long-lasting abdominal pain and considerable peripheral blood eosinophilia (34%; norm: $\leq 5\%$).

The patient, who was in his early twenties, had migrated to Germany 10 months before presentation and did not

report any diarrhoea or rectal bleeding. Upon clinical examination and abdominal ultrasound, no abnormalities were noted. A POC-CCA test was applied on urine on the day of presentation and gave a strongly positive test result (Figure 2), while the initial stool microscopy was negative and only few eggs of *S. mansoni* were detected upon repeated stool examination. No additional parasitic or bacterial intestinal infections were found during the further diagnostic workup. Based on the positive test result in the POC-CCA urine test, intestinal schistosomiasis was diagnosed and treatment with praziquantel promptly initiated. A follow-up visit for this patient is scheduled in June 2015.

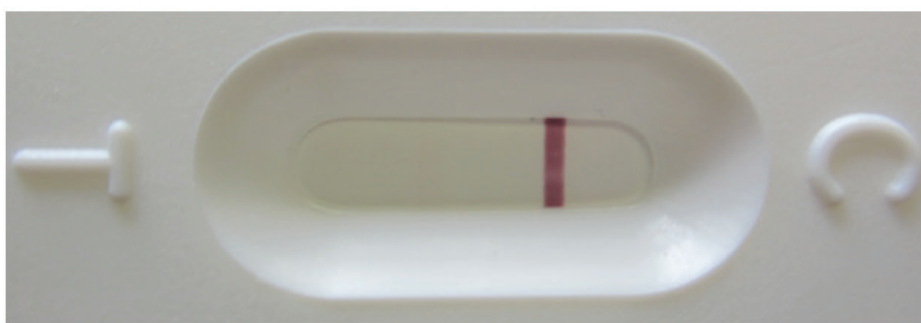
Discussion

Schistosomiasis is a parasitic disease that is endemic in large parts of sub-Saharan Africa, including Eritrea. The two main schistosome species in Africa are *S. mansoni* (causing intestinal schistosomiasis) and *S. haematobium* (causing urogenital schistosomiasis)


FIGURE 2

Results obtained by application of the point-of-care circulating cathodic antigen (POC-CCA) test for rapid diagnosis of *Schistosoma mansoni* infection on two patients' urine samples, Germany, February–May 2015

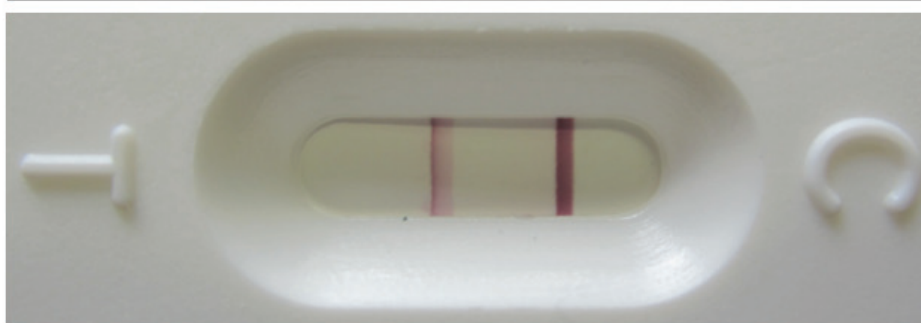
Negative Sample



Patient 1: Faintly positive test band



Patient 2: Strongly positive test band



The control band (C) is present in all three specimens, while a test band (T) is only present in positive samples and its strength may depend on the infection intensity.

[3-5]. Infection is acquired through contact with cercariae-infested freshwater bodies. More than 250 million people are infected with schistosomes [6,7]. While long-term morbidity from chronic *S. mansoni* infection can result in hepatic fibrosis, portal hypertension and hypersplenism [8], many infections may be missed due to the unspecific clinical presentation and the low sensitivity of the most widely used diagnostic assays (i.e. stool microscopy) [3].

Persistent abdominal pain and occasional blood in stool were the only symptoms reported by our patient 1, despite the significant inflammation observed in the intestinal mucosa. Inflammatory rectal polyps have been described as a feature of chronic *S. mansoni* infection [9-11], but schistosomiasis is rarely considered in the differential diagnosis of intestinal polyposis outside endemic areas [12]. In patient 2, the incidental finding of considerable peripheral blood eosinophilia

was the main reason to perform diagnostic tests pertaining to parasitic infections.

POC rapid diagnostic tests (RDTs) have the potential to improve the diagnosis and management of schistosomiasis patients. Thus far, repeated stool microscopy on several faecal specimens is the recommended diagnostic 'gold' standard, but light-intensity infections (i.e. ≤ 100 eggs per gram of stool) are often missed [3] and technical expertise in microscopic recognition of intestinal parasites is waning in many laboratories worldwide [13]. The urine-based POC-CCA is increasingly used in risk mapping and epidemiological surveys in schistosomiasis-endemic countries [1,14-16]. Previous studies have shown the positive and negative predictive values of a single POC-CCA to be 77% and 72-89%, respectively, if compared to multiple Kato-Katz thick smears as diagnostic reference standard [17,18]. The test has, however, not yet entered clinical practice in European hospitals and laboratories [7].

In our patient 1, the POC-CCA reliably detected the *S. mansoni* infection and confirmed the previously established histopathological diagnosis. Although polypectomy needed to be performed, an earlier use of a non-invasive urinary RDT may have provided evidence of active schistosomiasis more promptly. Indeed, in patient 2, the POC-CCA gave a positive test result on the first day of presentation, while helminth eggs of *S. mansoni* could only be detected upon repeated stool microscopy some days later. The clinical presentation of persistent abdominal pain and rectal bleeding is indicative of schistosomiasis in patients from endemic areas. A rapid diagnosis of this infection may allow faster adequate treatment, which in turn may lead to a resolution of the symptoms and avoid the need for further invasive diagnostic workup. While the POC-CCA is a highly sensitive and rapid tool to complement parasitological diagnostics, it cannot however replace a thorough microscopic examination of stool and urine, as the sensitivity for detection of *S. haematobium* is not sufficiently high [1], and no other parasites (e.g. soil-transmitted helminths) can be detected by POC-CCA.

Over the past decade, there has been a significant increase in migration from Africa and the Arabian Peninsula into Europe, with new arising challenges for the healthcare systems in various European countries [19]. Previous research has shown that inadequate communication and cultural barriers negatively affect the health-seeking behaviour of newly arrived Eritrean asylum seekers in Europe [20]. These immigrants may frequently present with imported infectious diseases that are not typically considered by European physicians in the differential diagnosis. A report from Sweden in 2014, for instance, has highlighted a dramatic increase of imported *Plasmodium vivax* malaria that was closely linked to newly arrived refugees from Eritrea [21]. While unexplained fever in African migrants usually prompts diagnostic testing for malaria, it is conceivable that rather unspecific gastrointestinal complaints, which are a key feature of many infections with helminths, including schistosomiasis, will not always lead to repeated stool sampling and in-depth diagnostic workup. Hence, we speculate that wider use of POC-CCA urine tests could improve the *S. mansoni* detection rate and, in turn, may reduce the number and costs of invasive diagnostic procedures.

Conclusions

Imported infections with *Schistosoma* spp. might increase in Europe due to a rise in migration from endemic settings, particularly from Africa. Due to the frequently unspecific clinical presentation of intestinal schistosomiasis and the insufficient sensitivity of stool microscopy, infections may easily be missed. We describe the successful use of POC-CCA urine tests for diagnosis of schistosomiasis and encourage physicians caring for migrants from endemic areas to consider implementing this rapid, relatively inexpensive (single test costs approximately EUR 1.50), and highly

sensitive test as part of the diagnostic workup for gastrointestinal disorders.

Acknowledgments

The patients are thanked for their consent which allowed us to publish this report. We are grateful to Dina Shouka for her assistance in taking photographs for Fig. 1.

Conflict of interest

None declared.

Authors' contributions

Patient examination, history taking and endoscopy: SZ, DV. Histopathological analysis: PAS, RMB. Microbiological diagnostics: SLB, HM, MH. Wrote the manuscript: SLB, MH, JU. All authors have read and approved the final version of the manuscript.

References

1. Colley DG, Binder S, Campbell C, King CH, Tchuem Tchuenté LA, N'Goran EK, et al. A five-country evaluation of a point-of-care circulating cathodic antigen urine assay for the prevalence of *Schistosoma mansoni*. *Am J Trop Med Hyg.* 2013;88(3):426-32. <http://dx.doi.org/10.4269/ajtmh.12-0639> PMID:23339198
2. Deutsche Gesellschaft für Tropenmedizin und Internationale Gesundheit (DTG). S1-Leitlinie: Diagnostik und Therapie der Schistosomiasis (Bilharziose). [S1 guideline : diagnosis and treatment of schistosomiasis (bilharzia)]. Version 07/2013. Arbeitsgemeinschaft der Wissenschaftlichen Medizinischen Fachgesellschaften (AWMF) online; July 2013. German. Available from: http://www.awmf.org/uploads/tx_szleitlinien/042-005l_S1_Diagnostik_Therapie_Schistosomiasis_2013-07.pdf
3. Utzinger J, Becker SL, Knopp S, Blum J, Neumayr AL, Keiser J, et al. Neglected tropical diseases: diagnosis, clinical management, treatment and control. *Swiss Med Wkly.* 2012;142:w13727. [10.4414/smw.2012.13727](http://dx.doi.org/10.4414/smw.2012.13727) PMID:23180107
4. Colley DG, Bustinduy AL, Secor WE, King CH. Human schistosomiasis. *Lancet.* 2014;383(9936):2253-64. [http://dx.doi.org/10.1016/S0140-6736\(13\)61949-2](http://dx.doi.org/10.1016/S0140-6736(13)61949-2) PMID:24698483</jrn>
5. <jrn>5. Lai YS, Biedermann P, Ekpo UF, Garba A, Mathieu E, Midzi N, et al. Spatial distribution of schistosomiasis and treatment needs in sub-Saharan Africa: a systematic review and geostatistical analysis. *Lancet Infect Dis.* 2015; (Forthcoming). [http://dx.doi.org/10.1016/S1473-3099\(15\)00066-3](http://dx.doi.org/10.1016/S1473-3099(15)00066-3) PMID:26004859
6. Hotez PJ, Alvarado M, Basáñez MG, Bolliger I, Bourne R, Boussinesq M, et al. The Global Burden of Disease study 2010: interpretation and implications for the neglected tropical diseases. *PLoS Negl Trop Dis.* 2014;8(7):e2865. <http://dx.doi.org/10.1371/journal.pntd.0002865> PMID:25058013
7. Utzinger J, Becker SL, van Lieshout L, van Dam GJ, Knopp S. New diagnostic tools in schistosomiasis. *Clin Microbiol Infect.* 2015; (Forthcoming). <http://dx.doi.org/10.1016/j.cmi.2015.03.014> PMID:25843503
8. Richter J, Bode JG, Blondin D, Kircheis G, Kubitz R, Holtfreter MC, et al. Severe liver fibrosis caused by *Schistosoma mansoni*: management and treatment with a transjugular intrahepatic portosystemic shunt. *Lancet Infect Dis.* 2015;15(6):731-7. [http://dx.doi.org/10.1016/S1473-3099\(15\)70009-5](http://dx.doi.org/10.1016/S1473-3099(15)70009-5) PMID:25769268
9. Nebel OT, el-Masry NA, Castell DO, Farid Z, Fornes MF, Sparks HA. Schistosomal disease of the colon: a reversible form of polyposis. *Gastroenterology.* 1974;67(5):939-43. PMID:4426495
10. el-Masry NA, Farid Z, Bassily S, Kilpatrick ME, Watten RH. Schistosomal colonic polyposis: clinical, radiological and parasitological study. *J Trop Med Hyg.* 1986;89(1):13-7. PMID:3091852
11. Mohamed AR, al Karawi M, Yasawy MI. Schistosomal colonic disease. *Gut.* 1990;31(4):439-42. <http://dx.doi.org/10.1136/gut.31.4.439> PMID:2110925

12. de Laval F, Savini H, Biance-Valero E, Simon F. Human schistosomiasis: an emerging threat for Europe. *Lancet*. 2014;384(9948):1094-5. [http://dx.doi.org/10.1016/S0140-6736\(14\)61669-X](http://dx.doi.org/10.1016/S0140-6736(14)61669-X) PMID:25241713
13. Yansouni CP, Merckx J, Libman MD, Ndao M. Recent advances in clinical parasitology diagnostics. *Curr Infect Dis Rep*. 2014;16(11):434. <http://dx.doi.org/10.1007/s11908-014-0434-9> PMID:25230603
14. Coulibaly JT, Knopp S, N'Guessan NA, Silué KD, Fürst T, Lohourignon LK, et al. Accuracy of urine circulating cathodic antigen (CCA) test for *Schistosoma mansoni* diagnosis in different settings of Côte d'Ivoire. *PLoS Negl Trop Dis*. 2011;5(11):e1384. <http://dx.doi.org/10.1371/journal.pntd.0001384> PMID:22132246
15. Lamberton PH, Kabatereine NB, Oguttu DW, Fenwick A, Webster JP. Sensitivity and specificity of multiple Kato-Katz thick smears and a circulating cathodic antigen test for *Schistosoma mansoni* diagnosis pre- and post-repeated-praziquantel treatment. *PLoS Negl Trop Dis*. 2014;8(9):e3139. <http://dx.doi.org/10.1371/journal.pntd.0003139> PMID:25211217
16. Mwinzi PN, Kittur N, Ochola E, Cooper PJ, Campbell CH Jr, King CH, et al. Additional evaluation of the point-of-contact circulating cathodic antigen assay for *Schistosoma mansoni* infection. *Front Public Health*. 2015;3:48. <http://dx.doi.org/10.3389/fpubh.2015.00048> PMID:25853117
17. Tchuem Tchuenté LA, Kueté Fouodo CJ, Kamwa Ngassam RI, Sumo L, Dongmo Noumedem C, Kenfack CM, et al. Evaluation of circulating cathodic antigen (CCA) urine-tests for diagnosis of *Schistosoma mansoni* infection in Cameroon. *PLoS Negl Trop Dis*. 2012;6(7):e1758. <http://dx.doi.org/10.1371/journal.pntd.0001758> PMID:22860148
18. Erko B, Medhin G, Teklehaymanot T, Degarege A, Legesse M. Evaluation of urine-circulating cathodic antigen (Urine-CCA) cassette test for the detection of *Schistosoma mansoni* infection in areas of moderate prevalence in Ethiopia. *Trop Med Int Health*. 2013;18(8):1029-35. <http://dx.doi.org/10.1111/tmi.12117> PMID:23590255
19. Rechel B, Mladovsky P, Ingleby D, Mackenbach JP, McKee M. Migration and health in an increasingly diverse Europe. *Lancet*. 2013;381(9873):1235-45. [http://dx.doi.org/10.1016/S0140-6736\(12\)62086-8](http://dx.doi.org/10.1016/S0140-6736(12)62086-8) PMID:23541058
20. Jonzon R, Lindkvist P, Johansson E. A state of limbo – in transition between two contexts: health assessments upon arrival in Sweden as perceived by former Eritrean asylum seekers. *Scand J Public Health*. 2015. [Epub ahead of print]. <http://dx.doi.org/10.1177/1403494815576786>
21. Sondén K, Castro E, Törnberg L, Stenström C, Tegnell A, Färnert A. High incidence of *Plasmodium vivax* malaria in newly arrived Eritrean refugees in Sweden since May 2014. *Euro Surveill*. 2014;19(35):20890. <http://dx.doi.org/10.2807/1560-7917.ES2014.19.35.20890>. Available from: <http://www.eurosurveillance.org/ViewArticle.aspx?ArticleId=20890> PMID:25210980